



Received on 27/07/2012;

Revised on 09/08/2012;


Accepted on 05/09/2012

## Review on Age Related Macular Degeneration

**Rathore K S., Vidhya Mudaliar**

B.N. Institute of Pharmaceutical Sciences, Udaipur, India

B.N. Girls College of Pharmacy, Udaipur



### Corresponding Author:

**Rathore K S.,**

Reader

B.N. Institute of Pharmaceutical Sciences, Udaipur,  
India

E mail: kamalsrathore@gmail.com

### ABSTRACT

Age-related macular degeneration (AMD) is the leading cause of visual impairment among older adults in the developed world. Epidemiological studies have revealed a number of genetic, ocular and environmental risk factors for this condition. AMD starts with deposits of lipid material that accumulate under the retinal pigment epithelium (RPE). These deposits, which appear as pale yellow spots on the retina, are called drusen. With increasing age, the RPE cells, which form the blood–retinal barrier, become less efficient and the retina is no longer able to receive the proper nutrition. This decline in the efficiency of the RPE cells also results in the accumulation of waste products (drusen). However, most people with evidence of drusen deposits maintain good vision. AMD results in central vision loss and is responsible for one-third of all forms of untreatable loss of vision. An estimated 9 million older Americans have some form of AMD, and about 1.75 million have advanced AMD. AMD is a disease of the elderly, and evidence suggests that 10% of individuals aged 65 to 74 years and 30% of those aged 75 to 85 years have evidence of AMD. AMD is a gradual, painless, irreversible process in which the patient loses bilateral vision.

**KEYWORD:** Retinal pigment epithelium, Drusen, Macula.

**(Review Article)****INTRODUCTION**

The retina is made up of two main layers. There is an inner layer of 'seeing cells' called rods and cones. These cells react to light and send electrical signals down tiny nerve fibres (which collect into the optic nerve) to the brain. The outer layer - the retinal pigment epithelium (RPE) - is a layer of cells behind the rods and cones. The RPE is an insulating layer between the retina and the choroid. These cells help to nourish and support the rods and cones. They pass nutrients from the blood vessels in the choroid to the rods and cones. They also take waste materials from the rods and cones to the blood vessels in the choroid. The RPE can be thought of as a filter, determining what substances reach the retina. Many components of blood are harmful to the retina and are kept away from it by a normally functioning RPE. The macula is a small but vital area of the retina at the back of your eye.

The macula is the part of the retina that is the most densely packed with rods and cones. The macula is essential for central vision. In the middle of the macula is an area called the fovea, which only contains cones. ARMD is a condition that occurs when cells in the macula degenerate. This occurs with partial breakdown of the RPE and the cells become damaged and die. Damage to the macula affects your central vision which is needed for reading, writing, driving, recognizing people's faces and doing other fine tasks. The rest of the retina is used for peripheral vision - the 'side' vision which is not focused. Therefore, without a macula you can still see enough to get about, be aware of objects and people, and be independent. However, the loss of central vision will severely affect normal sight.

**TYPES OF AGE RELATED MACULAR DEGENERATION**

DRY ARMD: Dry Macular Degeneration, also called Atrophic Macular Degeneration, is the most common type of Age Related Macular Degeneration. Dry Macular Degeneration makes up approximately 85-90% of cases of Macular Degeneration. Drusen is an aggregation of hyaline material located between Bruch's membrane and RPE. Drusen are composed of waste products from photoreceptors. Drusen > 63 microns in diameter are statistically associated with visual pathology and are termed early ARMD. Dry Macular Degeneration results in a slow, gradual progressive "dimming" of central vision. Geographic atrophy is the severest form of the dry macular degeneration representing a zone of RPE atrophy 175 microns or greater in diameter with exposure of the underlying choroidal vessels.

**WET ARMD**

Wet Macular Degeneration is far more likely to cause serious vision loss than Dry Macular Degeneration. Fortunately, it only accounts for about 10-15% of cases of Macular Degeneration. Wet Macular Degeneration is characterized by an abnormal growth of new blood vessel under the retina. These new blood vessels are called "neovascularization". Neovascularization is not made up of "normal" blood vessels in that they are unusually weak in their structure. In fact, they are quite fragile and are prone to be leaky and can easily break and bleed. If leakage occurs, the macula may actually begin to swell. If the new blood vessels break and bleeding occurs, it can result in scarring as it heals. Scarring of the macula can cause a sudden, rapid and severe loss of central vision, which is irreversible.

**Signs and Symptoms of ARMD**

ARMD is painless. Symptoms of dry ARMD tend to take 5-10 years to become severe. However, severe visual loss due to wet ARMD can develop more quickly.

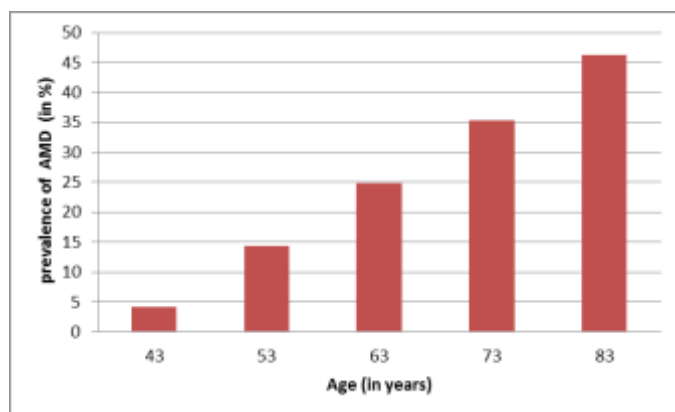
In the early stages of the condition you may notice that:

**(Review Article)**

- You need brighter light to read by.
- Words in a book or newspaper may become blurred.
- Colours appear less bright.
- You have difficulty recognising faces.
- One specific early symptom to be aware of is visual distortion. Typically, straight lines appear wavy or crooked. For example, the lines on a piece of graph paper, or the lines between tiles in a bathroom, or the border of any other straight object, etc.
- A 'blind spot' then develops in the middle of your visual field. This tends to become larger over time as more and more rods and cones degenerate in the macula.
- Visual hallucinations are common in people with severe visual loss of any cause.

**CAUSES AND RISK FACTORS**

Aging: Approximately 10% of patients 66 to 74 years of age will have findings of macular degeneration. The prevalence increases to 30% in patients 75 to 85 years of age.



Family history: The lifetime risk of developing late-stage macular degeneration is 50% for people that have a relative with macular degeneration, versus 12% for people that do not have relatives with macular

degeneration. Researchers from the University of Southampton reported that they had discovered six mutations of the gene SERPING1 that are associated with AMD. Mutations in this gene can also cause hereditary angioedema.

Macular degeneration gene: The genes for the complement system proteins factor H (CFH), factor B (CFB) and factor 3 (C3) are strongly associated with a person's risk for developing AMD. CFH is involved in inhibiting the inflammatory response mediated via C3b (and the alternative pathway of complement) both by acting as a cofactor for cleavage of C3b to its inactive form, C3bi, and by weakening the active complex that forms between C3b and factor B. C-reactive protein and polyanionic surface markers such as glycosaminoglycan normally enhance the ability of factor H to inhibit complement. But the mutation in CFH (Tyr402His) reduces the affinity of CFH for CRP and probably also alters the ability of factor H to recognise specific glycosaminoglycan. This change results in reduced ability of CFH to regulate complement on critical surfaces such as the specialised membrane at the back of the eye and leads to increased inflammatory response within the macula. In two 2006 studies, another gene that has implications for the disease, called HTRA1 (encoding a secreted serine protease), was identified.

High fat intake is associated with an increased risk of AMD in both women and men. Fat provides about 42% of the food energy in the average American diet. A diet that derives closer to 20-25% of total food energy from fat is probably healthier. Eating more cold-water fish (at least twice weekly), rather than red meats, and eating any type of nuts may help AMD patients.

Oxidative stress. Age-related accumulation of low-molecular-weight, phototoxic, pro-oxidant melanin oligomers within lysosomes in the retinal pigment epithelium may be partly responsible for decreasing the digestive rate of photoreceptor outer rod segments (POS) by the RPE. A decrease in the digestive rate of POS has been shown to be associated with lipofuscin formation - a classic sign associated with AMD.

**(Review Article)**

**Race.** Macular degeneration is more likely to be found in Caucasians than in people of African descent.

**Smoking.** Smoking tobacco increases the risk of AMD by two to three times that of someone who has never smoked, and may be the most important modifiable factor in its prevention. A review of previous studies found "the literature review confirmed a strong association between current smoking and AMD. Cigarette smoking is likely to have toxic effects on the retina."

**TREATMENTS**

There is no cure, but age-related macular degeneration treatments may prevent severe vision loss or slow the progression of the disease considerably. Several treatment options are available, including:

**Anti-angiogenic drugs.** These medications -- injected into the eye -- block the development of new blood vessels and leakage from the abnormal vessels within the eye that cause wet macular degeneration. This treatment has been a major change in the treatment of this condition and many patients have actually regained vision that was lost. The treatment may need to be repeated on follow-up visits.

**Laser therapy.** High-energy laser light can sometimes be used to destroy actively growing abnormal blood vessels that occur in age-related macular degeneration.

**Photodynamic laser therapy.** A two-step treatment in which a light-sensitive drug is used to damage the abnormal blood vessels. A medication is injected into the bloodstream to be absorbed by the abnormal blood vessels in the eye. The doctor then shines a cold laser into the eye to activate the drug, damaging the abnormal blood vessels.

**Vitamins.** A large study performed by the National Eye Institute of the National Institutes of Health, called AREDS -- Age-Related Eye Disease Study -- showed that for certain individuals, vitamins C, E, beta-carotene,

zinc, and copper can decrease the risk of vision loss in patients with intermediate to advanced dry age-related macular degeneration.

**Low vision aids.** Devices that have special lenses or electronic systems that produce enlarged images of nearby objects. They help people who have vision loss from macular degeneration make the most of their remaining vision.

Researchers are studying new age-related macular degeneration treatments. The following treatments are considered experimental.

**Submacular surgery.** Surgery to remove the abnormal blood vessels or blood.

**Retinal translocation.** A surgical procedure used to destroy abnormal blood vessels that are located directly under the center of the macula, where a laser beam cannot be placed safely. In the procedure, the macular center is rotated away from the abnormal blood vessels to a healthy area of the retina, thus preventing the formation of scar tissue and further damage to the retina. Once moved away from the abnormal blood vessels, a laser is used to treat the abnormal blood vessels.

**CONCLUSION**

Age-related macular degeneration is a serious eye disease.

A healthy diet, appropriate vitamin supplementation, and avoidance of smoking all help to slow down the progression of AMD.

Early detection and treatment, especially for wet AMD, can be crucial in preventing major vision loss. It is important for all older patients to have at least a yearly eye exam to screen for AMD. Once AMD is diagnosed, it is important to follow your doctor's advice about the frequency of eye examination so that treatable lesions can be detected early.

**REFERENCES**

1. Age-Related Eye Disease Study Research Group. Risk factors associated with age-related macular degeneration. A case-control study in the age-related eye disease study: Age-Related Eye Disease Study report number 3. *Ophthalmology* 2000, 107, 2224-32.
2. Khan J C, Thurlby D A, Shahid H, et al. Smoking and age related macular degeneration: the number of pack years of cigarette smoking is a major determinant of risk for both geographic atrophy and choroidal neovascularisation. *Br J Ophthalmol* 2006, 90, 75-80.
3. SanGiovanni J P, Chew E Y, Clemons T E, et al. The relationship of dietary carotenoid and vitamin A, E, and C intake with age-related macular degeneration in a case-control study: AREDS report number 22. *Arch Ophthalmol* 2007, 125, 1225-32.
4. Klein R J, Zeiss C, Chew E Y, et al. Complement factor H polymorphism in age-related macular degeneration. *Science* 2005, 308, 385-9
5. Piguet B, Wells J A, Palmvang I B, et al. Age-related Bruch's membrane change: a clinical study of the relative role of heredity and environment. *Br J Ophthalmol* 1993, 77, 400-3.
6. Seddon J M, George S, Rosner B. Cigarette smoking, fish consumption, omega-3 fatty acid intake, and associations with age-related macular degeneration: the US Twin Study of Age-Related Macular Degeneration. *Arch Ophthalmol* 2006, 124, 995-1001.